Kidney Res Clin Pract 32 (2013) 190–193

Kidney Research and Clinical Practice

journal homepage: http://www.krcp-ksn.com
Contents lists available at ScienceDirect

Case Report

A case of scrub typhus requiring maintenance hemodialysis

Dae-Yeon Kim [1], Hee-Soon Park [1], Dong-Jae Han [1], Hyo-Chul Kang [1], Ji-Hye Lee [2], Won-Jong Jang [3], Hyo-Wook Gil [1], Jong-Oh Yang [1], Eun-Young Lee [1,*], Sae-Yong Hong [1]

[1] Department of Internal Medicine, Soonchunhyang University Cheonan Hospital, Cheonan, Korea
[2] Department of Pathology, Soonchunhyang University Cheonan Hospital, Cheonan, Korea
[3] Institute of Glocal Disease Control and Department of Microbiology, College of Medicine, Konkuk University, Seoul, Korea

Article history:
Received 9 June 2013
Received in revised form
28 July 2013
Accepted 15 August 2013
Available online 5 November 2013

Keywords:
End-stage renal disease
Hemodialysis
Scrub typhus
Tubulointerstitial nephritis

Abstract

Renal failure caused by scrub typhus is known to be reversible. In most cases, renal function is almost fully restored after appropriate antibiotic treatment. A 71-year-old man was diagnosed with scrub typhus complicated by renal failure. A renal biopsy revealed histopathologic findings consistent with acute tubulointerstitial nephritis. Renal function did not improve 18 months after discharge and the patient required continuous hemodialysis. Although severe renal failure requiring dialysis is a rare complication of scrub typhus, we describe a case of scrub typhus requiring maintenance hemodialysis. To the best of our knowledge, this is the first such report.

© 2013. The Korean Society of Nephrology. Published by Elsevier. This is an open access article under the CC BY-NC-ND license (http://creativecommons.org/licenses/by-nc-nd/4.0/).

Introduction

Scrub typhus is an acute febrile illness characterized by fever, chills, myalgia, skin rash, lymphadenopathy, and an eschar at the site of the inoculating chigger bite. Scrub typhus, rickettsial infection (*Orientia tsutsugamushi*), is transmitted by trombiculid chigger mites (*Leptotrombidium* species). It is endemic in Southern and Eastern Asia including Northern Australia, and the Western Pacific Islands [1,2]. The spectrum of the clinical severity of scrub typhus ranges from mild to severe with fatal complications such as meningoencephalitis, pneumonitis, acute respiratory distress syndrome, acute kidney injury (AKI), myocarditis, disseminated intravascular coagulation (DIC), and septic shock [2–5].

The reported incidence of renal failure caused by scrub typhus varies from 10.5% to 42.6% according to the criteria of renal failure [6,7]. In most case reports, the serum creatinine level was restored after the administration of appropriate antibiotics such as doxycycline and azithromycin although varying degrees of renal deterioration and recovery time have been reported. To the best of our knowledge, no case of progression to end-stage renal disease has been reported for this condition. This is the first reported case of scrub typhus requiring maintenance hemodialysis.

Case report

A 71-year-old man was transferred to our university hospital from a private clinic because of significantly elevated serum creatinine. His serum creatinine level had been 1.2 mg/dL in the health screening examination performed 6 months prior to admission. Routine urine analysis was not performed at that time. His past medical history included diabetes mellitus for 10 years treated with oral hypoglycemic agents. The patient reported climbing mountains in the Jeolla province of Korea, 2 weeks prior to admission to our hospital. Four days later, he developed fever, chills, myalgia, and cough. The serum creatinine level was 11.0 mg/dL as measured at a private clinic, and the patient was transferred immediately to Soonchunhyang University Cheonan Hospital.

At the time of admission, vital signs were as follows: blood pressure, 170/90 mmHg; pulse rate, 87 beats/min; body

* Corresponding author. Division of Nephrology, Soonchunhyang University College of Medicine, 23-20 Bongmyung-dong, Cheonan 330–721, Korea.
E-mail address: eylee@sch.ac.kr (EY Lee).

2211-9132/$ - see front matter © 2013. The Korean Society of Nephrology. Published by Elsevier. This is an open access article under the CC BY-NC-ND license (http://creativecommons.org/licenses/by-nc-nd/4.0/).
http://dx.doi.org/10.1016/j.krcp.2013.09.003

temperature, 36.4°C; and respiratory rate, 20 breaths/min. The patient's mental status was alert. On physical examination, an eschar, which is characteristic of scrub typhus, was observed on the right arm near the axillary area. Complete blood cell counts were as follows: white blood cell count, 8.96×10^9/L; hemoglobin, 10.9 g/dL; hematocrit, 31.5%; and platelet count, 217×10^{12}/L. The results of arterial blood analysis were: pH, 7.31; arterial CO_2 tension, 25 mmHg; arterial O_2 tension, 90 mmHg; bicarbonate, 12.6 mM; and O_2 saturation, 96%. The biochemistry results were as follows: C-reactive protein (CRP), 78.54 mg/L; blood urea nitrogen, 91.6 mg/dL; creatinine, 14.1 mg/dL; sodium, 133 mEq/L; potassium, 5.8 mEq/L; and chloride, 103 mEq/L. Other significant laboratory findings were as follows: total protein, 5.7 g/dL; albumin, 3.1 g/dL; aspartate transaminase, 50 IU/L; alanine aminotransferase, 79 IU/L; uric acid, 11.0 mg/dL; creatinine phos phokinase, 128 IU/L; and lactate dehydrogenase, 652 IU/L. Microscopic urinalysis showed red blood cells $>$ 100/high-power field (HPF), white blood cells 50–99/HPF, and cast $<$ 1/HPF. The results of 24-hour urine analysis showed proteinuria at 934.5 mg/day. Serologic tests were all negative for rheumatoid factor, antinuclear antibody, hepatitis B and C virus, human immunodeficiency virus antibody, and syphilis (rapid plasma reagin test). Antistreptolysin O and complement levels were normal.

The patient had a history of outdoor activities and showed typical clinical manifestations of scrub typhus, especially an eschar in the right axillary area. The results of an immunochromatographic antibody assay test for *O. tsutsugamushi* was positive, and the immunofluorescent antibody assay test profile showed an immunoglobulin (Ig)M titer $>$ 1:2048 and IgG titer $>$ 1:2048. On the basis of these findings, he was diagnosed with scrub typhus. Doxycycline was administered 200 mg on the first day, followed by a maintenance dose of 100 mg once daily for 20 days.

For correction of hyperkalaemia, metabolic acidosis, and marked elevation of serum creatinine levels with uremic symptoms, the patient was started on hemodialysis on the first day of admission. After emergency management, he was placed on hemodialysis three times/week with conservative treatment. Clinically, the patient's symptoms improved dramatically while he was receiving doxycycline, showing a gradual decrease in inflammatory markers such as CRP. However, serum creatinine levels assessed prehemodialysis did not decrease continuously (Fig. 1).

We performed an ultrasonography-guided renal biopsy to rule out other underlying diseases, including diabetic nephropathy and primary glomerulonephritis, on Day 7 after admission. Microscopically, we detected diffuse lymphoplasmacytic infiltrations with scattered neutrophils in the edematous interstitium. Tubulitis and acute tubular necrosis were also observed. Detached tubular epithelial cells and neutrophils were detected in the tubular lumen. Mild tubular atrophy was also observed. The glomeruli were normal (Fig. 2), and no signs of mesangial expansion or glomerulosclerosis, which are common in diabetic nephropathy, were observed. However, vascular changes such as intimal fibrous thickening and medial sclerosis were severe.

The patient remained on hemodialysis three times/week, and he was discharged on Day 25 after admission. We expected the patient to recover his renal function gradually, but he remained on hemodialysis in an artificial kidney room of a private clinic for 18 months after discharge, and an arteriovenous fistula was formed. The patient's renal function did not improve, and his serum creatinine level remained at 8–10 mg/dL.

Discussion

In the present study, we describe a patient with renal failure caused by scrub typhus that did not show improvement of renal function despite a decrease in the levels of inflammatory markers such as CRP. The results of a renal biopsy showed microscopic findings suggestive of tubulointerstitial nephritis. Although case reports of patients with renal failure caused by scrub who underwent renal biopsy are rare, the presence of *O. tsutsugamushi* coccobacilli in the renal tubule has been reported previously [8]. In our patient, the presence of microorganisms was not verified.

Although the pathophysiology of renal failure as a complication of scrub typhus has not been fully elucidated, there are several possible hypotheses. First, because the basic pathologic characteristic of scrub typhus is multiorgan vasculitis of the small blood vessels, renal failure can be assumed to be associated with vasculitis [9,10]. A second possible explanation is DIC. Thrombosis and coagulation may induce microangiopathy and multiple organ damage, including AKI. A third explanation is prerenal azotemia caused by renal hypoperfusion

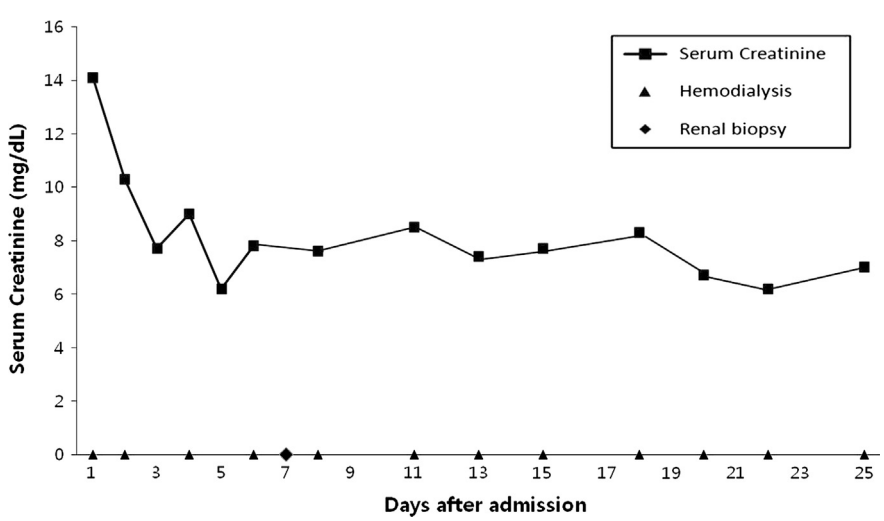

Figure 1. Time course of the changes in serum creatinine levels. Hemodialysis is indicated by arrowheads, and renal biopsy was performed at 7 days after admission.

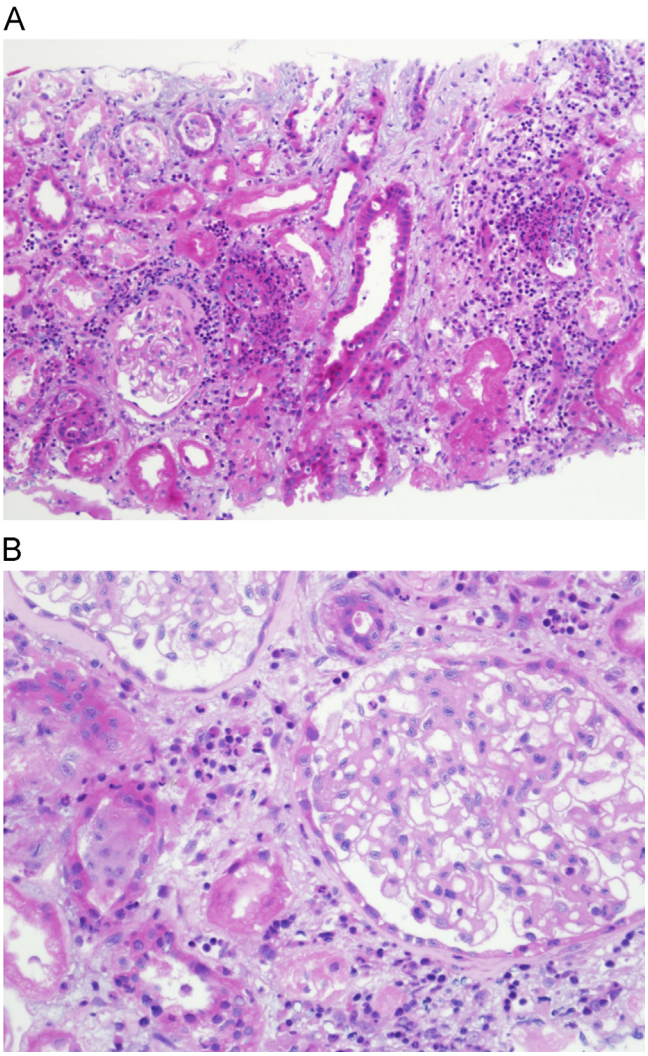

Figure 2. Histopathological findings of the renal biopsy specimen. (A) Multifocal infiltration of inflammatory cells including mononuclear cells and neutrophils is seen. Tubulitis and necrotic luminal debris are also seen. (B) All glomeruli observed are unremarkable.

associated with shock or volume depletion [8,9]. The effective renal blood flow decreases with increased vascular permeability, and this change is associated with systemic vasculitis. Widespread vascular damage causes leakage of plasma albumin into the perivascular space and hypoalbuminemia [11]. In addition, other nonspecific symptoms such as nausea, vomiting, poor oral intake, and diarrhea can be aggravated by volume depletion. However, in the present patient, there were no clinical and/or laboratory or histopathologic findings suggestive of vasculitis, DIC, or renal hypoperfusion. Finally, tubulointerstitial nephritis caused by direct invasion of the renal parenchyma by the microorganism may cause renal failure. Similar to our case, multifocal renal tubular necrosis and infiltration of inflammatory cells into the tubulointerstitium on renal biopsy were previously reported [8].

The reason for our patient's renal function not being fully recovered remains unclear. Several possible explanations associated with different pathophysiological mechanisms exist, as mentioned above. Renal hypoperfusion may have occurred prior to admission to our hospital. Because the patient was transferred from a private clinic, it is assumed that fluid therapy was performed to some extent. Infection by *O. tsutsugamushi* under these conditions may explain why renal function was not fully recovered. Another hypothesis is a superinfection or cross-reaction. In Korea, serologic surveys of patients have confirmed the prevalence of spotted fever group rickettsioses, including Japanese spotted fever. Because the clinical symptoms and signs of Japanese spotted fever are similar to those of scrub typhus, Japanese spotted fever may be misdiagnosed as scrub typhus [12,13]. In our patient, the antibody titer for *O. tsutsugamushi* by immunofluorescent antibody assay was $>1:2048$ and that for *Rickettsia japonica* was 1:1280. Although this is difficult to determine exactly because the presence of microorganisms was not verified, superinfection is possible. Furthermore, cross-reactions between *R. japonica* and *O. tsutsugamushi* have been reported although to a lesser extent than between *R. japonica* and typhus group rickettsia [14]. Finally, it is possible that the patient's baseline renal function was not normal. The estimated glomerular filtration rate according to the Cockroft–Gault equation and considering age, sex, and weight was 50 mL/minute 6 months prior to admission. In addition, severe vessel changes and mild tubular atrophy were observed in the biopsy specimen. According to the most recent report about renal failure due to scrub typhus, old age and underlying diseases such as hypertension, diabetes mellitus, and chronic kidney disease are predicting factor of AKI, but there are no cases of end-stage renal disease. Renal function of all patients was restored to the baseline after the administration of appropriate antibiotics. Therefore, although the patient's baseline renal function was slightly reduced, it is difficult to consider pre-existing renal dysfunction as a critical cause of permanent renal damage [15].

Renal failure caused by scrub typhus is commonly known to be reversible with the appropriate antibiotic therapy, and there are no reports of healthy adults requiring maintenance hemodialysis after scrub typhus infection. Physicians should reco gnize the possibility of permanent renal damage in patients with scrub typhus.

Conflict of interest

The authors have no conflicts of interest to disclose.

Acknowledgments

This research was supported by Basic Science Research Program through the National Research Foundation of Korea (NRF) funded by the Ministry of Education, Science and Technology (2012R1A1A2044121).

References

[1] Kim DM: Clinical features and diagnosis of scrub typhus. *Infect Chemother* 41:315–322, 2009
[2] McDonald JC, MacLean JD, McDade JE: Imported rickettsial disease: clinical and epidemiologic features. *Am J Med* 85:799–805, 1988
[3] Tsay RW, Chang FY: Serious complications in scrub typhus. *J Microbiol Immunol Infect* 31:240–244, 1998
[4] Han HW, Choi YK, Park MW, Park HS, Son DK, Lo DK, Kim SJ, Lee SY, Kim YK, Park SH: A case of scrub typhus with acute respiratory distress syndrome and meningoencephalitis. *Tuberc Respir Dis* 52: 283–287, 2002

[5] Lee S, Kang KP, Kim W, Kang SK, Lee HB, Park SK: A case of acute renal failure, rhabdomyolysis and disseminated intravascular coagulation associated with scrub typhus. *Clin Nephrol* 60: 59–61, 2003
[6] Kim DM, Kim HL, Park CY, Yoon SH, Song HJ, Shim SK: Scrub typhus: A prospective study of 76 cases. *Infect Chemother* 38:186–191, 2006
[7] Basu G, Chrispal A, Boorugu H, Gopinath KG, Chandy S, Prakash JA, Thomas K, Abraham AM, John GT: Acute kidney injury in tropical acute febrile illness in a tertiary care centre—RIFLE criteria validation. *Nephrol Dial Transplant* 26:524–531, 2011
[8] Kim DM, Kang DW, Kim JO, Chung JH, Kim HL, Park CY, Lim SC: Acute renal failure due to acute tubular necrosis caused by direct invasion of *Orientia tsutsugamushi*. *J Clin Microbiol* 46:1548–1550, 2008
[9] Yen TH, Chang CT, Lin JL, Jiang JR, Lee KF: Scrub typhus: a frequently overlooked cause of acute renal failure. *Ren Fail* 25:397–410, 2003
[10] Boyd AS, Neldner KH: Typhus disease group. *Int J Dermatol* 31: 823–832, 1992
[11] Dumler JS, Taylor JP, Walker DH: Clinical and laboratory features of murine typhus in south Texas, 1980 through 1987. *JAMA* 266: 1365–1370, 1991
[12] Jang WJ, Kim JH, Choi YJ, Jung KD, Kim YG, Lee SH, Choi MS, Kim IS, Walker DH, Park KH: First serologic evidence of human spotted fever group rickettsiosis in Korea. *J Clin Microbiol* 42:2310–2313, 2004
[13] Kim ES, Choi SRW, Lee JS, Chung MH, Lee HJ, Kim MJ, Kang JS, Jung SH, Oh BY: Seroprevalence of *Rickettsia japonica* on an island where a Korean patient with Japanese spotted fever was first identified. *Infect Chemother* 38:24–29, 2009
[14] Uchiyama T, Zhao L, Yan Y, Uchida T: Cross-reactivity of *Rickettsia japonica* and *Rickettsia typhi* demonstrated by immunofluorescence and Western immunoblotting. *Microbiol Immunol* 39:951–957, 1995
[15] Sun IO, Kim MC, Park JW, Yang MA, Lee CB, Yoon HJ, Kim JG, Lee KY: Clinical characteristics of acute kidney injury in patients with scrub typhus-RIFLE criteria validation. In: Proceedings of the 33rd Annual Spring Meeting of the Korean Society of Nephrology, 98, 2013 [Abstract]